

The Control of Bloodloss During Percutanerous Nephrolithotomy Using Tranexamic Acid

RALUCA COSTINA BARBILIAN^{1*}, VICTOR CAUNF², BOGDAN MIHAI², IOANA BURAGA¹, MIHAI DRAGUTESCU², DAN MISCHIANU^{3,4}

¹ATI Department, Colentina Clinical Hospital, 19-21 Stefan cel Mare Blvd., 020125, Bucharest, Romania

² Urology Department, Colentina Clinical Hospital, 19-21 Stefan cel Mare Blvd., 020125, Bucharest, Romania

³ Clinic of Urology Department, University Emergency Central Military Hospital Dr. Carol Davila, 134 Calea Plevnei, 010825, Bucharest, Romania

⁴ University of Medicine and Pharmacy, Clinical Department 3, 134 Calea Plevnei, 010825, Bucharest, Romania,

The aim of this study is to assess the efficiency and safety of the tranexamic acid in reducing hemmorrhagic complications and transfusion requirements in patients with renal lithiasis treated by percutaneous approach. Percutaneous nephrolithotomy (PCNL) is a minimally invasive technique used for large kidney stones (>20mm). Urinary sepsis and intra or postoperative bleeding are the very serious complications associated with this type of procedure. Tranexamic acid is used in the treatment of many haemorrhagic conditions. The experience with tranexamic acid in preventing bloodloss during percutaneous nephrolithotomy is very limited. The use tranexamic acid in percutaneous nephrolithotomy is safe and is associated with reduced blood loss and a lower transfusion rate.

Key words : percutaneous nephrolithotomy, PCNL, tranexamic acid

Renal lithiasis is a significant source of morbidity and costs in the present society. This disease affects a large cross-section of the population. Multiple genetic, metabolic and environmental risk factors are responsible for stone formation.

The percutaneous approach to the kidney was first described in 1955 by Goodwin and colleagues [1]. Over the past 20 years, percutaneous nephrolithotomy (PCNL) has replaced open renal surgery for the management of large upper urinary tract calculi.

Percutaneous nephrolithotomy (PCNL) is a minimally invasive technique used for large kidney stones (>20mm). Urinary sepsis and intra or postoperative bleeding are the very serious complications associated with this type of procedure. The indications for PCNL include staghorn calculi, ureteropelvic junction obstruction and calyceal diverticula (fig. 1), renal anomalies (horseshoe kidney), very hard stones (Hounsfield units ≥ 1000).



Fig.1 Multiple stones extracted via PCNL from a calyceal diverticulum. This image is from the author's personal database

Tranexamic acid is a synthetic derivative of the amino acid lysine that exerts its antifibrinolytic effect through the reversible blockade of lysine binding sites on plasminogen molecules (figs. 2 and 3). Intravenously administered tranexamic acid caused reductions in postoperative blood losses in patients undergoing cardiac surgery. Tranexamic acid is usually well tolerated; diarrhea and nausea are the most frequent adverse events [2].

Tranexamic acid is used in the treatment of many haemorrhagic conditions. The drug is used in spinal, orthopedic and general surgery to minimise postoperative

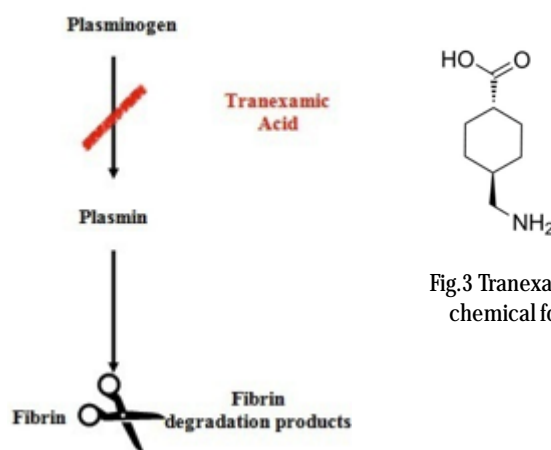


Fig.2 Tranexamic acid action. This image is from the author's personal database

blood loss and transfusion rate. The experience with tranexamic acid in reducing haemorrhagic complications in percutaneous nephrolithotomy is very limited.

Bleeding from the nephrostomy tract is the most common major complication associated with PCNL. The incidence of significant hemorrhage requiring transfusion in modern reported series of PCNL ranges from 10 to 25% [3,4].

The purpose of this paper is to assess the efficiency and safety of the tranexamic acid in reducing hemmorrhagic complications and transfusion requirements in patients with renal lithiasis treated by percutaneous approach.

Experimental part

The data of 71 patients diagnosed with renal lithiasis which underwent percutaneous nephrolithotomy between 1st october 2016 - 1st march 2018. Regional anesthesia was used in most cases (87.3%). The percutaneous access was completed through a single percutaneous tract in most partients; 2 tracts were required in 7 cases (Figures 4 and 5). Second look PCNL was used in 4 cases. Exclusion criterias included coagulopathies, back problem disorders, neurological disorders with paresthesia and patient refusal.

*email: barbilianraluca@yahoo.com; Phone: 021.317.32.45/5020

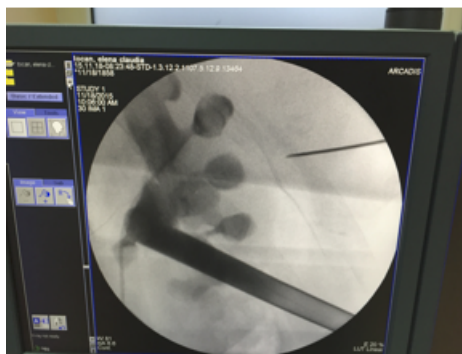


Fig.4 PCNL with 2 puncture tracts. This image is from the author's personal database

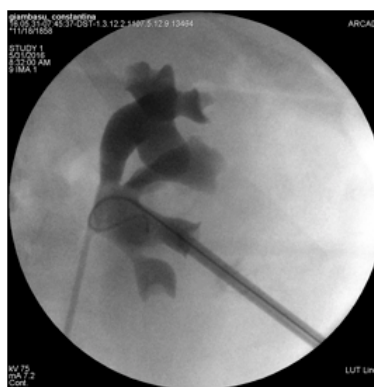

Fig.5 PCNL tract dilation. This image is from the author's personal database

Double J stenting for lumbar fistula was performed in 5 cases. Three more double J stents were placed at the end of surgery for ureteropelvic junction obstruction.

Holmium:YAG laser, ultrasonic or ballistic fragmentation were used for lithotripsy. Plain renal X ray was used to measure stone diameter; abdominal ultrasound or computed tomography was used to measure the size of radiolucent stones. All the patients were worked up with an intravenous urography or contrast computed tomography; profilactic antibiotic therapy was used in patients with positive urine cultures.

Postoperative evaluation at 72 hours included abdominal ultrasound and plain renal X ray. The one month evaluation was done using abdominal ultrasound, plain renal X ray or computed tomography.

The patients were divided in two groups : 37 (group 1) received 1 g of tranexamic acid at induction followed by oral doses (500 mg at every 8 h during the first 24 h), while 34 patients (group 2) did not receive the tranexamic acid. The clinical data of the patients were compared.

Most of the PCNL-s (87.3% - 62 patients) were performed under regional anesthesia because of better postoperative pain relief, more benign postoperative recovery and because of the intersurgical communication with the patient.

All patients were premedicated with 3 mg Midazolam. 1 hour prior to surgery 23 patients received 1 g Exacyl (tranexamic acid) in 250 mL saline solution 0.9% with slow infusion (1 h); infusion with the same posology was repeated 12 h postsurgery.

The chosen anesthesia was spinal block. The patients were placed in sitting position on the operating table. Respecting the mandatory aseptic conditions, using a 26-27 gauge Quincke spinal needle, a dural puncture was made at L2-L3 interspaces and 12 mg of hyperbaric Marcaine 0.5 % was administrated in subarachnoidal space.

Results and discussions

The mean age of the patients was 59 years and the mean stone size was 28mm (range 17- 58 mm). The mean operative time was shorter for the tranexamic acid group (68 min) compared to the control group (74 min).

The stone free rate was 83%. The postoperative complications were represented by postoperative pain (25.3%), hematuria (16.89%), fever (9.8%), urinary sepsis (3 cases - 4.2%). The mean hemoglobin drop in the tranexamic acid group was significantly lower than that of the control group (1.1 g vs 2.6 g). The transfusion rate was also higher in the control group (9 patients vs. 2 patient).

Kukreja and colleagues [5] in 2004 analyzed the factors affecting blood loss during PCNL. In a group of 301 procedures analyzed prospectively, the factors associated with significant blood loss were diabetes, multiple tracts, prolonged operative times, and the occurrence of intraoperative complications. Higher blood loss was

associated with metal dilators versus Amplatz or balloon dilation.

Tranexamic acid was successfully used in many surgical procedures : spinal, orthopedic, and general surgery [6,7].

The use of tranexamic acid has a low complication rate [8]. A meta-analysis conducted by Ker and al. concluded that tranexamic acid reduces the need for blood transfusion in surgery, although thromboembolic events and mortality remains uncertain [9].

The tranexamic acid was used before in prostate surgery (transurethral resection of the prostate or radical prostatectomy) with good results. Crescenti and al. reported for radical retropubic prostatectomy in patients with prostate cancer a reduction in transfusion rate of 21% and a relative risk of transfusion requirements for patients treated with tranexamic acid of only 0.62 with no statistical differences in thromboembolic events between the two groups [10].

The experience with tranexamic acid in preventing bloodloss during percutaneous nephrolithotomy is very limited .

Kumar et al published promising results in a prospective randomized controlled study in 2013; the mean hemoglobin drop, transfusion requirements and operative time were significantly lower in patients who received tranexamic acid [11,12].

Conclusions

The use of tranexamic acid for reducing hemmorrhagic complications during and after percutaneous nephrolithotomy is a safe method. It minimises the blood loss and has a lower transfusion rate. More studies are required in order to evaluate the role of the tranexamic acid as an antifibrinolytic agent in preventing blood loss during percutaneous nephrolithotomy.

References

- 1.GOODWIN W.E., CASEY W.C., WOOLF W., Percutaneous trocar (needle) nephrostomy in hydronephrosis, J. Am. Med. Assoc., 157, nr. 11, 1955, p. 891-4.
- 2.DUNN C.J., GOA K.L., Tranexamic acid: a review of its use in surgery and other indications, Drugs, 57, nr. 6, 1999, p. 1005-32.
- 3.DAVIDOFF R., BELLMAN G.C., Influence of technique of percutaneous tract creation on incidence of renal hemorrhage, J. Urol., 157, 1997, p. 1229-31.
- 4.GALLUCCI M., FORTUNATO P., SCHETTINI M., VINCENZONI A., Management of hemorrhage after percutaneous renal surgery, J. Endourol., 12, 1998, p. 509-12.
- 5.KUKREJA R., DESAI M., PATEL S., ET AL., Factors affecting blood loss during percutaneous nephrolithotomy: prospective study, J. Endourol., 18, nr. 8, 2004, p. 715-22.
- 6.FERGUSON D.A., HÉBERT P.C., MAZER C.D., FREMES S., MACADAMS C., MURKIN J.M., ET AL., A comparison of aprotinin and lysine analogues in high-risk cardiac surgery, N. Engl. J. Med., 358, 2008, p. 2319-31;

- 7.KIM C., SI-HYEONG PARK S., RODERICK DAVEY J., Tranexamic acid for the prevention and management of orthopedic surgical hemorrhage: current evidence, *J. Blood. Med.*, 6, 2015 p. 239-44.
- 8.HENRY D.A., CARLESS P.A., MOXEY A.J., O'CONNELL D., STOKES B.J., FERGUSON D.A., KER K., Anti-fibrinolytic use for minimising perioperative allogeneic blood transfusion. *Cochrane Database Syst. Rev.*, 16, nr. 3, 2011.
- 9.KER K., EDWARDS P., PEREL P., SHAKUR H., ROBERTS L., Effect of tranexamic acid on surgical bleeding: systematic review and cumulative meta-analysis, *B.M.J.*, 344, 2012, p.1-13.
- 10.CRESCENTIA., BORCHI G., BIGNAMIE., BERTARELLI G., LANDONI G., CASIRAGHI G.M., BRIGANTI A., MONTORSI F., RIGATTI P., ZANGRILLO A., Intraoperative use of tranexamic acid to reduce transfusion rate in patients undergoing radical retropubic prostatectomy: double blind, randomised, placebo controlled trial, *B.M.J.*, 343, 2011.
- 11.KUMAR S., RANDHAWA M.S., GANESAMONI R., SINGH S.K., Tranexamic acid reduces blood loss during percutaneous nephrolithotomy: a prospective randomized controlled study, *J. Urol.*, 189, nr. 5, 2013, p. 1757-61.
12. EMILIA MANOLE, LAURA CRISTINA CEAFALAN, ANA-MARIA OPROIU, AUREL POPA-WAGNER, BOGDAN OVIDIU POPESCU, Claudin-1 and occludin expression in demyelinating peripheral neuropathies, *Rom J Morphol Embryol*, 2015, 56(3):1097-1102

Manuscript received:23.03.2018